

## REVIEW ARTICLE

**Functional and clinical neuroanatomy of morality**

Manuela Fumagalli and Alberto Priori

Dipartimento di Scienze Neurologiche, Università degli Studi di Milano, Fondazione IRCCS Ca' Granda, Ospedale Maggiore Policlinico, 20122 Milano, Italy

Correspondence to: Prof. Alberto Priori, MD, PhD  
Dipartimento di Scienze Neurologiche,  
Fondazione IRCCS Ca' Granda,  
Ospedale Maggiore Policlinico,  
Via Francesco Sforza 35,  
20122 Milano, Italy  
E-mail: alberto.priori@unimi.it

Morality is among the most sophisticated features of human judgement, behaviour and, ultimately, mind. An individual who behaves immorally may violate ethical rules and civil rights, and may threaten others' individual liberty, sometimes becoming violent and aggressive. In recent years, neuroscience has shown a growing interest in human morality, and has advanced our understanding of the cognitive and emotional processes involved in moral decisions, their anatomical substrates and the neurology of abnormal moral behaviour. In this article, we review research findings that have provided a key insight into the functional and clinical neuroanatomy of the brain areas involved in normal and abnormal moral behaviour. The 'moral brain' consists of a large functional network including both cortical and subcortical anatomical structures. Because morality is a complex process, some of these brain structures share their neural circuits with those controlling other behavioural processes, such as emotions and theory of mind. Among the anatomical structures implicated in morality are the frontal, temporal and cingulate cortices. The prefrontal cortex regulates activity in subcortical emotional centres, planning and supervising moral decisions, and when its functionality is altered may lead to impulsive aggression. The temporal lobe is involved in theory of mind and its dysfunction is often implicated in violent psychopathy. The cingulate cortex mediates the conflict between the emotional and the rational components of moral reasoning. Other important structures contributing to moral behaviour include the subcortical nuclei such as the amygdala, hippocampus and basal ganglia. Brain areas participating in moral processing can be influenced also by genetic, endocrine and environmental factors. Hormones can modulate moral behaviour through their effects on the brain. Finally, genetic polymorphisms can predispose to aggressivity and violence, arguing for a genetic-based predisposition to morality. Because abnormal moral behaviour can arise from both functional and structural brain abnormalities that should be diagnosed and treated, the neurology of moral behaviour has potential implications for clinical practice and raises ethical concerns. Last, since research has developed several neuromodulation techniques to improve brain dysfunction (deep brain stimulation, transcranial magnetic stimulation and transcranial direct current stimulation), knowing more about the 'moral brain' might help to develop novel therapeutic strategies for neurologically based abnormal moral behaviour.

**Keywords:** aggressiveness; behavioural neurology; behaviour; brain; psychiatry

**Abbreviations:** COMT = catechol-O-methyltransferase; tDCS = transcranial direct current stimulation; MAOA = monoamine oxidase A

## Introduction

Abnormal moral behaviour implies the violation of ethical rules and civil rights and often results in violence and criminal acts. Moral behaviour is the product of a complex process that although somehow primed by genes and environment, is ultimately controlled by the brain. Since the 1990s, both behavioural and neuroscientific studies of morality have grown in volume and sophistication. In particular, the interest in the neurobiological determinants of human ethics prompted neuroscientists to address several intriguing issues, including whether specific neuronal networks or anatomical brain structures exist for moral behaviour. Besides bringing about a major advance in neuroscience and in the biology of mind, understanding the neural foundations of morality could help in developing novel strategies for treating abnormal moral behaviours. It also has potentially important social implications. For instance, developing a treatment for serial sexual assaulters could help prevent further crimes, reduce the number of victims and diminish the need for imprisonment and ultimately, benefit society.

In this article, to understand better the functional and clinical neuroanatomy of morality, we review and integrate findings from studies in various fields (clinical neurology and psychiatry, neuroimaging, neurophysiology, neuropathology, behavioural genetics and psychoneuroendocrinology) investigating moral judgement, moral behaviour and violent behaviour, considered as the behavioural expression of moral abnormality. Unlike previous reviews on morality (Moll *et al.*, 2005; Raine and Yang, 2006; Young and Koenigs, 2007; Funk and Gazzaniga, 2009; Huebner *et al.*, 2009; Moll and Schulkin, 2009), we discuss studies on healthy subjects and on patients with neurological and psychiatric disorders through a neuroanatomical approach. To highlight the complexity and multiple faceted neural control of morality we also consider the role of genes and hormones. Although abnormal moral behaviour can be part of several neurological and psychiatric disturbances, for the purposes of this review we focus on conditions primarily characterized by violent behaviour that could be attributed to moral abnormality.

## Violence as the behavioural consequence of moral abnormality

Several tests can now be used to measure morality in experimental studies (tasks that use philosophical moral dilemmas, tasks that present visual sentences and tasks that present pictures) (Greene *et al.*, 2001; Moll *et al.*, 2001; Harenski and Hamann, 2006), and for clinical purposes, scales and questionnaires are available to assess abnormal moral behaviour (Rush *et al.*, 2008).

From a behavioural point of view, the major consequence of moral abnormality is violence. Violence stems from multiple factors including social learning, frustration, cognitive and moral development, mental and neurological disorders, environmental and genetic factors (Fabian, 2010). Their cumulative effect portends

a behaviourally negative outcome, such as psychopathy, criminality, murder, substance abuse disorder, homelessness and unemployment (Fabian, 2010). Aggression can be defined as 'any form of behaviour directed towards the goal of harming or injuring another living being who is motivated to avoid such treatment' (Baron and Richardson, 2004). Aggression can be secondary to focal cerebral disease or related to brain abnormalities in individuals with no other overt signs of a cerebral disorder (David *et al.*, 2009). Aggression becomes violence when it is exaggerated and unjustifiable, leading to violation of social norms and to destruction (Victoroff, 2009). To fulfil the aims of this review, among psychiatric disorders we will consider psychopathy, sociopathy and antisocial personality disorders. A critically important denominator shared by all these conditions is the failure to conform to the commonly accepted mores of society that often ultimately results in abnormal moral behaviour.

## Frontal lobe

### Healthy subjects

Neuroimaging studies demonstrate that a brain region closely involved in moral judgement is the ventromedial prefrontal cortex (Greene *et al.*, 2001; Moll *et al.*, 2001, 2002a, b; Heekeren *et al.*, 2003; Borg *et al.*, 2006; Harenski and Hamann, 2006; Luo *et al.*, 2006; Prehn *et al.*, 2008; Harenski *et al.*, 2009; Young and Saxe, 2009; Shenhav and Greene, 2010; Sommer *et al.*, 2010). The ventromedial prefrontal cortex has a critical role in encoding the emotional value of sensory stimuli (Rolls, 2000), and its recruitment during moral decisions supports ventromedial prefrontal cortex involvement in their emotional processing (Greene *et al.*, 2001; Moll *et al.*, 2002a, b; Heekeren *et al.*, 2003). The ventromedial prefrontal cortex is also implicated in allowing one to adhere to social norms and cultural values (Moll *et al.*, 2005), and in representing preferences about others' outcomes according to perceived intentions (Cooper *et al.*, 2010). The left ventromedial prefrontal cortex is more intensely activated in subjects with lower ability to apply moral principles in justifying the resolution of moral dilemmas (Prehn *et al.*, 2008). Ventromedial prefrontal cortex/medial orbitofrontal cortex activation also correlates with the 'expected moral value' of decision options, defined as the expected number of lives lost/saved (Shenhav and Greene, 2010). Promising research developments over recent years include studies designed to modulate moral judgement with non-invasive brain stimulation techniques [transcranial direct current stimulation (tDCS) and transcranial magnetic stimulation] over the different areas of the frontal lobe. tDCS entails applying weak direct currents through an electrode on the scalp for a time ranging from seconds to minutes (Fox, 2011). This technique induces prolonged changes in cortical excitability: anodal stimulation generally increases and cathodal stimulation decreases cortical excitability (Priori, 2003; Utz *et al.*, 2010), respectively depolarizing or hyperpolarizing the neuronal membrane (Accornero *et al.*, 2007). When Koenigs *et al.* (2009) delivered bilateral prefrontal tDCS to 25 subjects doing a moral judgement task they failed to obtain statistically significant results. In a study conducted in our

laboratory (Fumagalli *et al.*, 2010), we administered a moral judgement task to 78 healthy subjects before and after anodal or cathodal tDCS applied over the ventral prefrontal cortex or occipital cortex. In female subjects, we found that, whereas anodal prefrontal tDCS significantly increased utilitarian responses, cathodal prefrontal tDCS tended to decrease them. According to Greene *et al.* (2008) and Greene (2007), a utilitarian choice aims at 'maximizing benefits and minimizing costs across affected individuals' (Greene *et al.*, 2008), 'endorsing harmful actions that promote the greater good' (Greene, 2007). Hence, anodal ventral prefrontal tDCS interferes with utilitarian decisions specifically in females. We hypothesized that anodal stimulation reduces the prefrontal activity in emotional evaluation and does so by mimicking the effect of a lesion. A possible explanation for gender difference is that tDCS modulates the female tendency towards altruism more easily than the male tendency. Whereas altruism in males 'resists' tDCS-induced changes, altruism in females might be more sensitive to small, transient changes induced by stimulation. Because dopamine is an anionic catecholamine that migrates towards the anode during electrophoresis, anodal ventral prefrontal tDCS might act by increasing dopamine levels in the frontal lobe, thus influencing the dopamine reward circuit and ultimately altering decisional processes, increasing utilitarian response rates. Though several methodological reasons make it difficult to compare the study conducted by Koenigs *et al.* (2009) with the one conducted in our laboratory (Fumagalli *et al.*, 2010), our finding provides new evidence that brain stimulation (tDCS) is able to modulate moral judgement and behaviour (at least under laboratory conditions).

The rational counterpart of the ventromedial prefrontal cortex is the dorsolateral prefrontal cortex. This frontal lobe area is involved in problem-solving and cognitive control (Greene *et al.*, 2004) and competes with the ventromedial prefrontal cortex in suppressing prepotent emotional reactions (Greene *et al.*, 2004). Specifically, in moral judgement the dorsolateral prefrontal cortex has a pivotal role in aggregating cost-benefit analysis and in utilitarian moral reasoning (Greene *et al.*, 2001, 2004), intervenes in evaluating situations that recruit rule-based knowledge (Prehn *et al.*, 2008), and in deciding on responsibility for crimes and on appropriate punishment (Haushofer and Fehr, 2008). The dorsolateral prefrontal cortex is also activated during dishonest behaviour, probably reflecting the process of lying (Greene and Paxton, 2009). tDCS over the dorsolateral prefrontal cortex also influences deceptive responses (Priori *et al.*, 2008; Mameli *et al.*, 2010).

Other brain regions involved in moral processing are the cingulate cortex (Greene *et al.*, 2001, 2004; Harenski *et al.*, 2008) and the left subgenual gyrus (Luo *et al.*, 2006). The anterior cingulate cortex mediates the 'conflict' between the emotional and the rational components of moral reasoning, whereas the posterior cingulate cortex is more closely related to emotion and social ability (Greene *et al.*, 2001, 2004).

In conclusion, data in healthy subjects show that the frontal lobe drives moral behaviour and that the role of the various frontal areas probably differs during moral decision processing: whereas the orbital and ventromedial prefrontal cortices emotionally drive moral decisions, the dorsolateral prefrontal cortex acts mainly as a

rational 'filter'. This dual opposite processing involving the ventromedial prefrontal cortex and the dorsolateral prefrontal cortex seems to be mediated by the anterior cingulate cortex.

## Patients

The first clinical evidence showing a link between personality, behaviour, morality and the frontal lobe came from studies on patients. In 1848, while Phineas Gage was working on a railroad line, an accidental explosion drove a steel rod up into his left cheek and through his frontal lobes. A local physician, Harlow, described him as fitful, irreverent, impatient of restraint or advice when it conflicts with his desires, and also obstinate and capricious (Feldman and Goodrich, 2001). In 1936, on the basis of animal experiments conducted by John Fulton, Egas Moniz proposed surgically cutting the connections between the frontal cortex and the thalamus (leucotomy) to treat certain psychoses (Heller *et al.*, 2006). In his article on psychosurgery, Moniz reported good results also in severely agitated, anxious or depressed patients (Moniz, 1937). Quenching the original enthusiasm for brain surgery as a viable means of combating mental illness, in 1942 Walter Freeman reported the results for 200 lobotomy cases and acknowledged that the procedure was not always benign: 14% of the patients who underwent prefrontal lobectomy subsequently manifested seizures and impaired cognition, affect, mood and social behaviour (Feldman and Goodrich, 2001). After surgery these patients also exhibited a severe frontal syndrome, altered abstract thinking and judgement (Feldman and Goodrich, 2001), and various personality changes. Freeman described patients as

'... lazy, rude, boisterous, restless and inane [...] [the patient] is relatively unteachable, having lost those social skills that are necessary for living outside an institution [...]. If the patient has previously demonstrated antisocial traits such as alcoholism, drug addiction, criminality, avoidance of responsibility, aggressiveness or psychopathic activities, the effect of operation may be to free him from any residual sense of guilt or shame, and thus turn loose upon society an individual whose behavior is intolerable' (Freeman, 1950).

Hence, surgical procedures involving the frontal cortex and frontal tracts reportedly achieved successes or failures: the symptoms were reduced or, conversely, as Freeman reported, exacerbated. The main reason for these opposing results is probably the lack of homogeneity in the procedures used by Moniz and Freeman (Freeman, 1950; Knight, 1969). The lack of neuroimaging techniques, the psychopathological heterogeneity of patients, the lack of quantitative outcome variables and of neuropathological controls in studies reporting the results of frontal leucotomy and other psychosurgical interventions make it difficult to understand from historical data how surgery affects the frontal lobe in humans. Whatever the clinical results, surgery and lesions of the frontal lobe can induce moral changes thus further demonstrating the key role of this structure in moral behaviour.

Reviewing 25 previously published studies of post-lesion acquired antisocial personality disorders and 39 studies of post-lesion acquired obsessive-compulsive disorders, Braun *et al.* (2008)

found that the most typical lesion causing antisocial personality disorder is that involving the ventromedial prefrontal cortex, occasionally spreading to the caudate nucleus (Braun *et al.*, 2008). In an early study by Feuchtwanger (1923) cited in David *et al.* (2009), comparing patients with frontal gunshot wounds with patients in whom bullets penetrated other parts of the skull, frontal lesions induced euphoria, irritability, aggressivity, apathy, attention deficits and moral defects (David *et al.*, 2009). Acquired lesions to the frontopolar and to the ventromedial prefrontal cortex at an early age may lead to even more severe impairments in moral behaviour, suggesting that the prefrontal cortex is involved in moral development (Eslinger *et al.*, 1992; Anderson *et al.*, 1999). Patients with ventromedial prefrontal cortex lesions also have a significantly high frequency of moral disturbances with aggressive and violent behaviour. They also typically seem disinhibited, impulsive and unconcerned with the consequences of their behaviour (Rolls *et al.*, 1994; Grafman *et al.*, 1996; Brower and Price, 2001), a neurological syndrome significantly defined as 'acquired sociopathy' (Saver and Damasio, 1991). These observations are consistent with animal studies showing that lesions in the orbitofrontal cortex are related to uncontrolled aggression (Butter *et al.*, 1970; Elliott, 1990). Patients with ventromedial prefrontal cortex damage retain the knowledge of social rules, recognize the elements that compose social situations, for example current contingencies, possible response options and future outcomes (Saver and Damasio, 1991), but they cannot make appropriate decisions in natural settings. This inadequate decisional processing makes them insensitive to the future positive or negative consequences of an action. The 'somatic marker model' explained the reduced anticipatory skin conductance in response to stimuli predicting negative outcomes observed in these patients as an inability to mark the implications of a decision with a signal that automatically distinguishes advantageous from pernicious actions (Damasio *et al.*, 1990; Damasio, 1994). Systematic studies about the impairment of social and moral behaviour related to damage to the ventromedial prefrontal cortex reported various explanations. For example they proposed that moral judgements in these patients are characterized by an abnormal high rate of utilitarian judgements for moral dilemmas in which social emotions play a pivotal role in resolving moral conflict (Ciaramelli *et al.*, 2007; Koenigs *et al.*, 2007; Moretto *et al.*, 2009; Thomas *et al.*, 2011) or by more morally permissive judgements for failed attempts to harm (Young *et al.*, 2010b). Focusing on how patients justify moral judgements, others suggest that patients' justifications do not reflect normal adult levels of moral reasoning but are characterized by egocentrism (Anderson *et al.*, 1999).

The 'somatic marker model' and these data suggest that moral reasoning relies on both rational/conscious and emotional/unconscious processing in the ventromedial prefrontal cortex. Prefrontal involvement, measured in terms of reduced grey matter in this area, is also reported in antisocial and psychopathic individuals (Raine *et al.*, 2000; Yang *et al.*, 2005), and in aggressive patients with temporal lobe epilepsy (Woermann *et al.*, 2000). In the neuroimaging literature, reduced prefrontal glucose metabolism is associated with acts of aggressive impulsive behaviour (Goyer *et al.*, 1994), with antisocial personality disorder (Bufkin and Luttrell, 2005), and characterizes murderers compared with

normal controls (Raine *et al.*, 1994). Superior and ventrolateral prefrontal activity also positively correlated with psychopathy in an emotion regulation task (Harenski *et al.*, 2009), whereas in moral/non-moral picture distinctions, ventromedial prefrontal cortex activity is more severely reduced in psychopaths than in non-psychopaths (Harenski *et al.*, 2010) (Fig. 1). New imaging evidence for the neural bases of moral and prosocial sentiments comes from a study in patients with the behavioural variant of frontotemporal dementia engaged in a moral sentiment task that highlighted a role of the medial frontopolar cortex (Moll *et al.*, 2011).

Anterior cingulate cortex lesions result in persistent behavioural changes, in particular reduced and occasionally increased aggressivity, disinhibition, impulsivity, emotional blunting and decreased motivation (Devinsky *et al.*, 1995).

Current knowledge from studies in patients therefore suggests that the frontal structures most directly involved in abnormal moral behaviour are the medial orbitofrontal cortex and ventromedial prefrontal cortex.

## Temporal lobe and insula

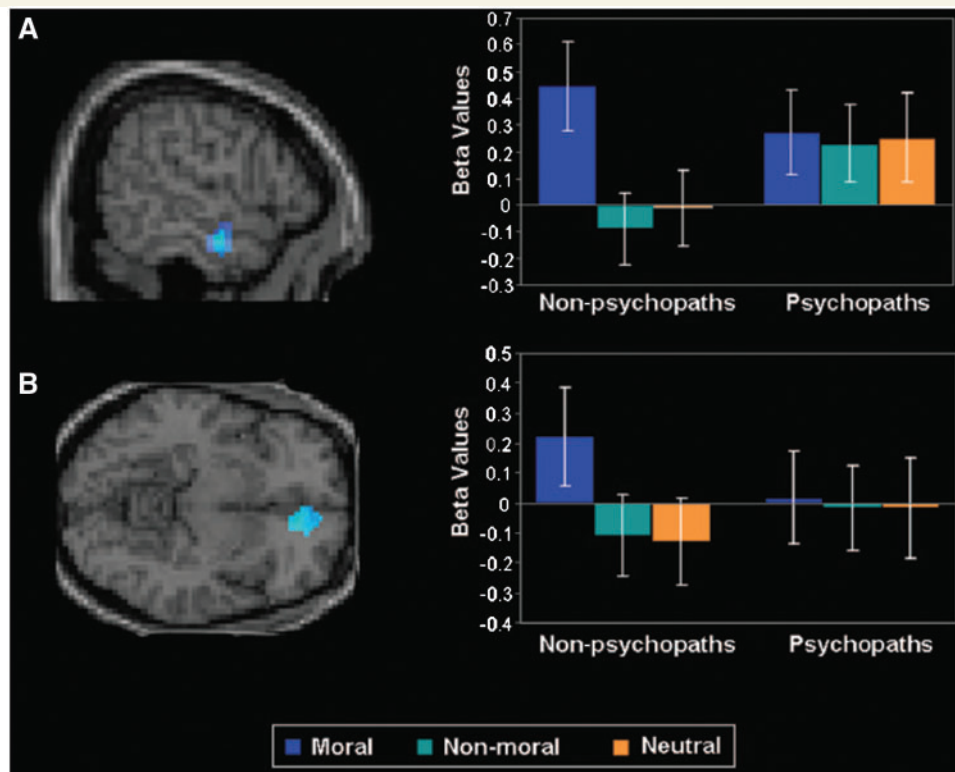
### Healthy subjects

A further important structure for moral behaviour is the temporal lobe. Neuroimaging studies found that a temporal lobe region involved in moral judgement is the superior temporal sulcus (Moll *et al.*, 2001, 2002a, b; Heekeren *et al.*, 2003, 2005; Greene *et al.*, 2004; Borg *et al.*, 2006; Harenski and Hamann, 2006). Superior temporal sulcus activates during the elaboration of moral dilemmas because it is associated with emotion (Greene *et al.*, 2004), during processing of social cognition mechanisms (Moll *et al.*, 2002b; Greene *et al.*, 2004) and in making decisions about complex ethical dilemmas (Heekeren *et al.*, 2003; Greene *et al.*, 2004).

Another region implicated in moral function includes the anterior/middle temporal gyrus (Moll *et al.*, 2001; Heekeren *et al.*, 2003, 2005; Greene *et al.*, 2004; Harenski and Hamann, 2006; Sommer *et al.*, 2010). Accordingly, some researchers retain that these areas are activated after the point of decision, in particular when subjects choose a utilitarian response, suggesting that neural processing of moral conflict is associated with higher cognitive demands (Greene *et al.*, 2004; Sommer *et al.*, 2010).

A further temporal region activated during moral dilemma evaluation (Greene *et al.*, 2001) and involved in evaluating moral agency and responsibility (Borg *et al.*, 2006) is the angular gyrus.

The temporo-parietal junction (Young *et al.*, 2007; Kedia *et al.*, 2008; Harenski *et al.*, 2009; Young and Saxe, 2009) contributes to moral intuition (spontaneous, unsolicited attention directed towards cues that have potential moral salience such as a person in distress, weapons or emotion-laden words) (Harenski *et al.*, 2009), and to belief attribution during moral judgement (Young *et al.*, 2007; Young and Dungan, 2011). Neurostimulation studies also support a direct link from theory of mind to moral judgement. Theory of mind is a person's intuitive ability to understand other



**Figure 1** Analyses of brain activity during moral picture viewing showed a significant interaction between psychopaths/non-psychopaths and moral versus non-moral and neutral picture viewing in the anterior temporal cortex (A) and in ventromedial prefrontal cortex (B). This finding indicates that non-psychopaths showed a significantly greater moral than non-moral and neutral picture distinction in these regions, whereas psychopaths did not. Error bars are standard errors. (Copyright © 2010 by the American Psychological Association. Reproduced with permission from Harenski *et al.*, 2010. The use of APA information does not imply endorsement by the APA).

people's plans, thoughts, points of view, beliefs, attitudes and emotions. Transcranial magnetic stimulation applied to the right temporo-parietal junction before or during a moral judgement task led subjects to rely less on the actor's mental states, judging attempted harms as less morally forbidden and more morally permissible (Young *et al.*, 2010a).

Finally, insular cortex activation is found during various moral tasks (Moll *et al.*, 2002b; Greene *et al.*, 2004; Borg *et al.*, 2008; Kedia *et al.*, 2008; Cooper *et al.*, 2010) and is related to emotional processing (Greene *et al.*, 2004; Kedia *et al.*, 2008), to disgust processing (Moll *et al.*, 2002b) and to detecting and processing uncertainty (Cooper *et al.*, 2010). Other studies reported that the insula is more strictly involved in moral processing and sensitive to norm violations implicated in deontological judgement (Huebner *et al.*, 2009): it is activated in the perception of inequity (Hsu *et al.*, 2008) and in care and justice cognition (Caceda *et al.*, 2011).

In conclusion, available findings in healthy subjects imply that, although not necessarily engaged in moral decisions, the insular cortex is involved in emotional processing and in encoding inequity. The anterior/middle temporal gyrus has a secondary role, being recruited during working memory and general cognitive processing. Whereas the superior temporal sulcus

evaluates the intentionality and social complexity of moral actions, the temporo-parietal junction has a role in belief attributions and theory of mind, two basic requirements for moral processing.

## Patients

The first observation about the temporal lobe's role in moral and violent behaviour comes from psychosurgery. In 1891, Burckhardt removed the temporal lobe in five patients with intractable psychiatric disturbances who he described as demented and aggressive, with unsuccessful results (Berrios, 1997). Temporal lobe resection is a surgical procedure also used to treat patients with temporal lobe epilepsy, who often experience psychiatric, cognitive and behavioural manifestations (Hamberger and Drake, 2006; Schramm, 2008; David *et al.*, 2009). This procedure is able to solve behavioural disorders, although patients continue to experience cognitive disturbances involving memory and language. Although no studies have specifically investigated moral decisions in patients with temporal lobe epilepsy and in patients who underwent temporal lobe resection, their behavioural abnormalities could at least partly reflect damage to limbic structures, in particular the amygdala. Anatomical studies showed reduced temporal

lobe volume in patients with early-onset conduct disorder (Kruesi *et al.*, 2004), in incarcerated psychopaths (Dolan *et al.*, 2002) and in antisocial personality disorders (Barkatki *et al.*, 2006). In line with anatomical observations, neuroimaging studies documented reduced temporal lobe activation in aggressive patients (Volkow and Tancredi, 1987; Amen *et al.*, 1996), psychopaths (Soderstrom *et al.*, 2000) and violent offenders (Raine *et al.*, 2001). Electroencephalographic recordings also disclose right temporal lobe abnormalities in patients with aggressive antisocial behaviour (David *et al.*, 2009).

Structural abnormalities and volume losses in the right superior temporal gyrus have been reported in psychopathic individuals (Müller *et al.*, 2007 cited in Weber *et al.*, 2008). Activation deficits in this brain area are reported in antisocial and psychopathic patients during a semantic processing task, showing that psychopaths used more cognitive resources to process affective information than did healthy subjects (Kiehl *et al.*, 2004).

Reduced bilateral activation in the middle temporal gyrus is also a typical neuroimaging finding in aggressive children with temporal lobe epilepsy (Juhasz *et al.*, 2001), antisocial patients (Goethals *et al.*, 2005), violent psychiatric patients (Volkow *et al.*, 1995) and violent offenders (Seidenwurm *et al.*, 1997; Soderstrom *et al.*, 2000).

Reduced activation is reported also in the anterior temporal cortex in violent patients (Wong *et al.*, 1997) and in psychopaths during a moral decision-making task (Fig. 1) (Harenski *et al.*, 2010). Anterior temporal lobe involvement in psychopaths seems to be related specifically to reduced ability to process morally salient stimuli, restricting moral processing to generation of semantic and emotional context (Harenski *et al.*, 2010).

Among temporal structures, the hippocampus has an important role in emotion and behaviour. A significant negative correlation was found between the posterior hippocampal volume and degree of psychopathology in repetitive violent offenders (Laakso *et al.*, 2001), and a specific abnormal hippocampal morphology in the absence of total grey matter volume changes characterizes habitually violent offenders (Boccardi *et al.*, 2010). These data fit well with the hippocampal role in the acquisition and retrieval of fear conditioning (Burman *et al.*, 2006; Tsetsenis *et al.*, 2007), and in aggressive and impulsive behaviour (Guillot *et al.*, 1994; Sluyter *et al.*, 1996; Deakin, 2003; Prior *et al.*, 2004; Cardinal, 2006; van Goozen and Fairchild, 2006). Last, hippocampal stimulation in humans elicits severe rage reactions (Heath, 1992). Using depth electrodes in patients with epilepsy with aggressive behaviour, Saint-Hilaire *et al.* (1981) recorded epileptic activity localized to the right hippocampus during a spontaneous aggression.

Finally, ictal electroencephalographic recordings in aggressive patients with temporal seizures show that the epileptic activity during spontaneous epileptic aggressive behaviour localizes first in the right amygdala, then in the right temporal cortex, right hippocampus and parahippocampal gyrus and then reaches the anterior and median cingulate gyrus and right supplementary motor area (Saint-Hilaire *et al.*, 1981).

Right insular lesions are associated with low emotional intelligence, poor judgement in decision-making and disturbances in social functioning (Bar-On *et al.*, 2003). Bilateral grey matter reduction in the insula are reported in psychopaths

(de Oliveira-Souza *et al.*, 2008). Fear conditioning activates insula in healthy subjects but not in psychopaths (Birbaumer *et al.*, 2005), suggesting that the emotional processing for anticipated pain and for threat stimuli is impaired in patients.

In conclusion, studies from patients argue that various temporal areas, in particular the superior temporal gyrus, the middle temporal gyrus and the anterior temporal cortex, are closely related to moral judgements and violent behaviour. The hippocampus is consistently associated with violent-aggressive behaviour and is involved in the development of moral constitution (Laakso *et al.*, 2001).

## Parietal lobe

### Healthy subjects

Some functional neuroimaging studies report inferior parietal lobe activation during moral processing (Greene *et al.*, 2004; Harenski *et al.*, 2008; Caceda *et al.*, 2011). The study by Greene *et al.* (2004) suggests that this brain area is associated with working memory and cognitive control, so that it is recruited because the task proposed engaged cognitive processing.

### Patients

Whereas, to our knowledge, no published data are available on parietal lesions or abnormalities and moral behaviour, neuroimaging studies disclose increased blood flow in the parietal cortex in non-psychotic violent offenders (Soderstrom *et al.*, 2000). In murderers (Raine *et al.*, 1997) and individuals with impulsive personality disorders (Siever *et al.*, 1999) metabolism—investigated using functional MRI and PET—was reduced in the superior parietal cortex.

In conclusion, despite the scant literature, although available data argue that the parietal lobe contributes to moral judgement and is involved in abnormal moral behaviour, its precise function in processing moral decisions is still unknown.

## Subcortical structures

### Healthy subjects

Only few functional MRI studies have found subcortical involvement during moral processing. The amygdala activates during processing of both basic and moral emotions (Moll *et al.*, 2002b), during evaluation of moral judgement (Greene *et al.*, 2004), during violation of severity ratings for moral pictures (Harenski *et al.*, 2008) and during personal desire-oriented decisions in contrast to morally guided responses (Sommer *et al.*, 2010). Amygdala activation is reduced during passive viewing of moral and non-moral pictures when individuals attempted to decrease emotions (Harenski and Hamann, 2006) and in response to bodily harm (Heekeren *et al.*, 2005). Amygdala activation induced by bodily harm may reflect amygdala-specific involvement in affective judgements about the emotional value of an action

(Heekeren *et al.*, 2005), and could imply reduced moral brakes when the individual is in danger.

Bilateral thalamic activation can be observed during decisions on whether to follow a moral rule or fulfil a personal desire (Sommer *et al.*, 2010), whereas activation in the septal region is related to charitable donations (Moll *et al.*, 2006).

The caudate nucleus is activated during the evaluation of moral stimuli (Luo *et al.*, 2006), in charitable living (Harbaugh *et al.*, 2007) and in altruistic punishment (de Quervain *et al.*, 2004).

The amygdala therefore appears to be a pivotal subcortical structure involved in processing moral emotions.

## Patients

Evidence that subcortical structures intervene in morality is further supported by data from patients. Disinhibition and violent behaviour are related to grey matter loss or volume loss or structural amygdala abnormalities in violent offenders (Wong *et al.*, 1997; Tiihonen *et al.*, 2000; Van Elst *et al.*, 2000) and in psychopathic individuals (Yang *et al.*, 2006). Why amygdalotomy improves 30–40% of patients with severe behavioural disturbances, aggressiveness and violent behaviour (Fountas and Smith, 2007) therefore remains unclear. A possible explanation is that amygdala dysfunction causes patients' behavioural abnormalities and aggressiveness. In these instances, surgery to remove dysfunctional amygdala can restore normal behaviour. Neuroimaging studies during various tasks report inconsistent results on amygdala responses: two functional MRI studies reported increased amygdala activation in antisocial individuals viewing negative visual content (Müller *et al.*, 2003) and during an aversive conditioning task (Schneider *et al.*, 2000). In contrast, others report reduced amygdala activation during the processing of negative affective stimuli in criminal psychopaths (Kiehl *et al.*, 2001), in fear conditioning in criminal psychopaths (Veit *et al.*, 2002; Birbaumer *et al.*, 2005), in response to emotional stimuli in adolescents with conduct disorders (Sterzer *et al.*, 2005) and during emotional moral decision-making in psychopathy (Glenn *et al.*, 2009). Another study comparing psychopaths and healthy subjects during a moral decision-making task found that psychopaths lacked a positive association between amygdala activity and the severity of moral violation ratings, suggesting a reduced emotional response (Harenski *et al.*, 2010). Collectively, findings in patients agree with those in healthy subjects and confirm a pivotal role of the amygdala in processing moral emotions. In line with structural and neuroimaging studies, stimulation studies also showed amygdala involvement in emotion and violence expression. Heath *et al.* (1955) described the case of a patient receiving amygdala stimulation who became enraged and attacked the psychiatrist. Some studies in Treiman's (1991) review also reported aggressive behaviour during amygdala stimulation. The amygdala might therefore represent a sort of 'switch' between brain processing of moral emotions and their translation into action and aggression.

Impulsive-antisocial temperament of psychopathic patients is related to neurochemical and functional nucleus accumbens alterations during monetary reward anticipation. The role of this structure in psychopathic behaviour probably reflects its participation

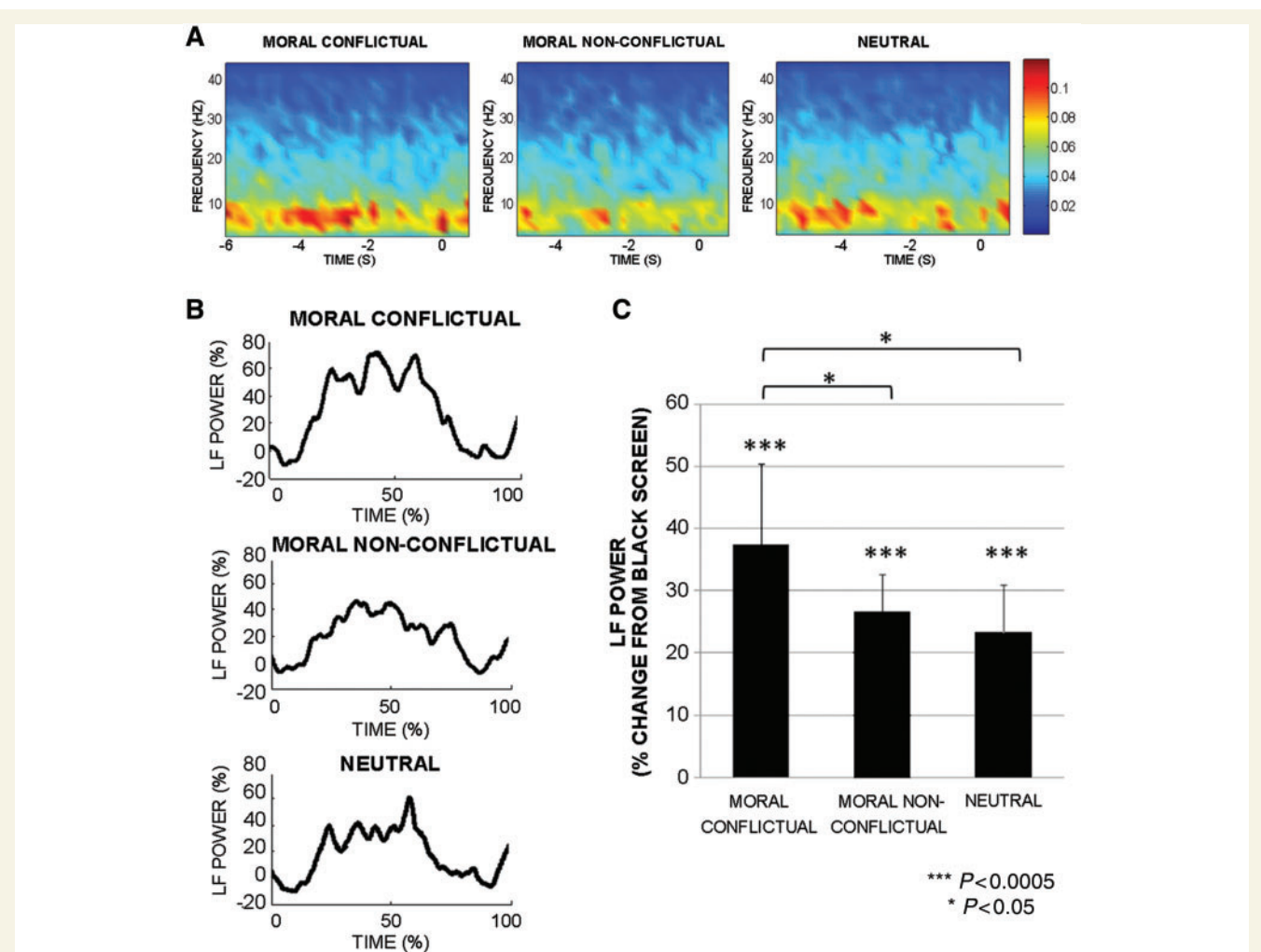
in the mesolimbic dopaminergic system, involved in reward and impulsive behaviour (Buckholz *et al.*, 2010).

Early evidence suggesting the role of the septum in empathy, guilt and remorse in psychopathy (Gorenstein and Newman, 1980) has now been corroborated by a PET study reporting hypometabolism in the septal region while patients with the behavioural variant of frontotemporal dementia executed a moral sentiment task (Moll *et al.*, 2011).

Accidental stimulation of the posteromedial hypothalamic area by deep brain stimulation induced aggressive behaviour in patients with Parkinson's disease (Bejjani *et al.*, 2002; Sensi *et al.*, 2004). In contrast, deep brain stimulation of the posterior hypothalamus improved patients with disruptive behaviour and mental retardation (Franzini *et al.*, 2005; Hernando *et al.*, 2008; Kuhn *et al.*, 2008).

In patients with Parkinson's disease, subthalamic nucleus deep brain stimulation can occasionally induce mild personality changes, disinhibition, mood changes, hypersexuality and pathological gambling (Temel *et al.*, 2005), ultimately influencing moral behaviour. Neurophysiological studies over the past 10 years have described subthalamic activity changes in local field potentials recorded through the stimulation electrodes implanted for deep brain stimulation in patients with Parkinson's disease engaged in various cognitive and behavioural tasks (Kuhn *et al.*, 2005; Brucke *et al.*, 2007; Marceglia *et al.*, 2009, 2011; Fumagalli *et al.*, 2011). In a study conducted in our laboratory to assess the role of basal ganglia in moral decision-making and in the processing of moral conflictual stimuli (Fumagalli *et al.*, 2011), we recorded subthalamic local field potentials from 16 Parkinsonian patients doing a moral task. The task required patients to evaluate moral conflictual, moral non-conflictual and neutral sentences, and to respond if they agreed or disagreed by pressing one of two buttons. The results showed that a specific subthalamic rhythm, low-frequency band (5–13 Hz), is involved in decision processing: the subthalamic nucleus intervenes in moral judgement in a conflict-dependent way, its oscillations being specifically modulated by moral conflictual stimuli. These findings extend the 'moral brain' to encompass the basal ganglia including the subthalamic nucleus, especially for conflict processing (Fumagalli *et al.*, 2011) (Fig. 2).

In summary, available data argue for subcortical participation in the brain network responsible for moral reasoning. The amygdala has a crucial role in processing social and emotional content and in particular in learning that some actions harm others and should therefore be avoided (Blair, 2007). Amygdala structural and functional impairments mean that psychopathic individuals and criminals are unable to recognize cues that signal threat, becoming relatively fearless and more readily engaged in antisocial behaviour (Sterzer, 2010). Finally, the septal area is involved in empathy and altruism and its hypometabolism is associated with impairments on prosocial sentiments, such as pity and guilt (Moll *et al.*, 2011). Emerging evidence suggesting that subcortical structures intervene in abnormal moral behaviour might indicate directions for future research on the therapeutic effects of deep brain stimulation in psychopathic disorder and violent behaviour.



**Figure 2** Subthalamic local field potentials in patients with Parkinson's disease during a moral decision task. (A) Time–frequency plots of grand average subthalamic nucleus local field potentials in each task condition (moral conflictual, moral non-conflictual, neutral). The x-axis shows the time (s) from the mean reaction time value of the task condition to 1 s after the choice. The sentence evaluation phase starts from sentence presentation to 500 ms before key pressing (time = 0). Note that during the moral task, low-frequency power (5–13 Hz) increased during sentence evaluation. (B) Low-frequency (LF) power modulation during the sentence evaluation for each task condition shows higher modulation during moral conflictual sentences. (C) Histograms represent the mean low-frequency modulation in sentence evaluation during each task condition. Note the significantly higher power modulation during the moral conflictual condition. In conclusion, subthalamic local field potential recordings show strong subthalamic nucleus activation especially during conflictual moral decisions. Error bars represent the confidence interval of the estimated mean ( $1.96 \times$  standard error). (Reprinted from Fumagalli *et al.*, 2011, with kind permission of Taylor & Francis Ltd. <http://www.informaworld.com>).

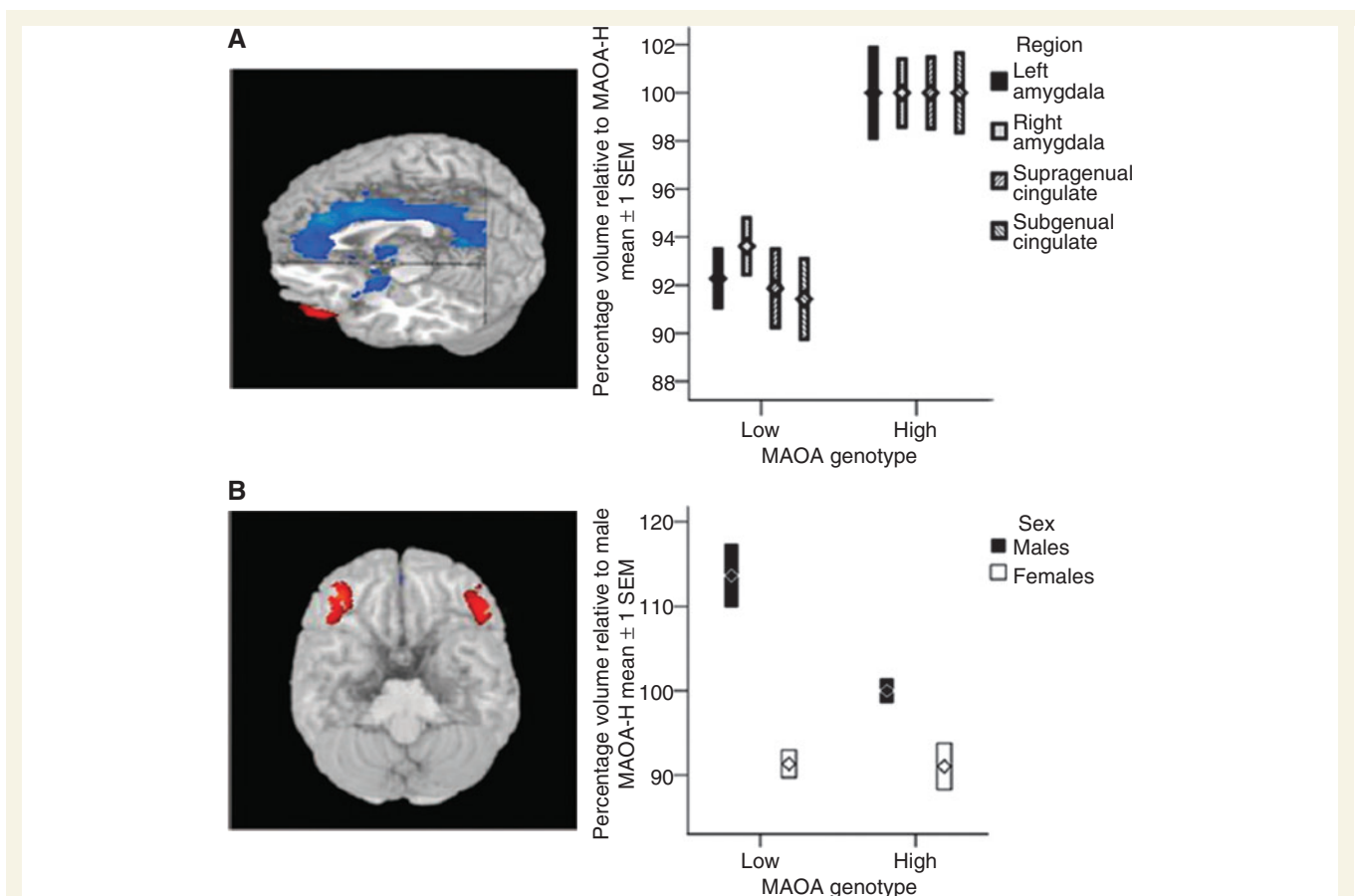
## Genes and hormones

Two centuries ago, the Italian criminologist Cesare Lombroso suggested that phenotypic features revealed the criminal attitude of the individual. The general concept that genetic alterations, abnormalities in the brain and its functioning can be linked to criminal behaviour nowadays attracts interest (Pietrini and Bambini, 2009). Geneticists have shown that complex behavioural disorders can partly arise from variations in DNA sequences and environmental factors. Family, twin and adoption studies have all suggested that genetic factors contribute to antisocial personality disorders and externalizing behaviours. Genetic and non-shared environmental factors are both important in the development of

psychopathy. The weight of the two factors is debated, but increasing evidence shows that genetic factors account for 49–81% of the variance and in psychopathy are more important than environment (Gunter *et al.*, 2010).

The brain catecholaminergic systems regulate aggressive behaviour. Two major enzymes are responsible for catecholamine catabolism in the brain: monoamine oxidase A (MAOA) and catechol-O-methyltransferase (COMT). The MAOA gene is located on the X chromosome. The MAOA enzyme preferentially catabolizes the brain neurotransmitters noradrenaline and serotonin (Volavka *et al.*, 2004). The remarkable consequences of MAOA gene deletions in mice suggest that mild functional variations in this gene probably have significant behavioural impacts





**Figure 3** The correlation between the MAOA polymorphism and brain structure and function assessed with MRI in healthy humans. (A) Individuals with the low-expression variant associated with an increased risk of violent behaviour compared with subjects with the high-expression variant exhibit significant volume reductions in bilateral amygdala, suprageneal anterior cingulate and subgeneal anterior cingulate cortex. (B) Male individuals with the low-expression variant show greater lateral orbitofrontal volume, bilaterally, than subjects with the high-expression variant. No genotype effect was found in females, indicating a highly significant sex  $\times$  genotype interaction. Plots represent the summed volumes of voxels in predefined region of interest, normalized to volume measures relative to the high-expression variant of the MAOA gene (MAOA-H) group mean (100%). [Reprinted from Meyer-Lindenberg *et al.*, 2006, with kind permission of National Academy of Sciences, USA—Copyright (2011) National Academy of Sciences, USA].

(Shih *et al.*, 1999). In humans, the first proof of a link between aggressivity and MAOA came from a study investigating a Dutch family with a repeated incidence of violent criminal behaviour among males across several generations all of whom had a MAOA gene abnormality (Brunner *et al.*, 1993). Low MAOA activity, combined with traumatic early life events, seems to increase the likelihood of antisocial disturbances in adults (Caspi *et al.*, 2002; Meyer-Lindenberg *et al.*, 2006; McDermott *et al.*, 2009) (Fig. 3). Low enzymatic COMT activity is associated with increased brain catecholamine levels that raised the likelihood of aggression (Volavka *et al.*, 2004). Consistent with this expectation, COMT knockout mice exhibited increased aggressive behaviour (Gogos *et al.*, 1998) and in humans, the COMT Met allele is associated with aggressive behaviour in males (Craig and Halton, 2009).

As well as genetic factors, hormones can profoundly influence behaviour and cognition by interfering with brain metabolism and neuronal function. Areas implicated in social and emotional processing have extensive connections with peripheral physiological functioning, and specifically, have strong reciprocal connections

with the endocrine system. Whereas the hypothalamus–pituitary–gonadal axis is involved in the reproductive and immune systems (Terburg *et al.*, 2009), the hypothalamic–pituitary–adrenal axis is entailed in the limbic emotion-related neurocircuitry. The end product of the hypothalamic–pituitary–adrenal axis is cortisol and the end product of the hypothalamus–pituitary–gonadal axis is testosterone. Cortisol is a key modulator of several emotion-related learning and memory processes, of social behaviour, and is also associated with anxiety symptoms. The brain network involved in cortisol regulation includes the prefrontal cortex, insula, amygdala and anterior cingulate cortex. In particular, the prefrontal cortex is implicated in hypothalamic–pituitary–adrenal axis inhibition and regulation and insular activity in response to traumatic stimuli is associated with adrenocorticotrophic hormone responsivity (Shirtcliff *et al.*, 2009). Finally, anterior cingulate cortex hypoactivation indicates reduced cortisol reactivity and is associated with callousness (Shirtcliff *et al.*, 2009), whereas hyperactivation means increased cortisol reactivity and is related to social stressors (Eisenberger *et al.*, 2007). Extensive behavioural

endocrinology research associated reduced hypothalamic–pituitary–adrenal axis functioning in children and adolescents with the development of psychopathy (van Honk and Schutter, 2006). Lower cortisol levels characterize psychopathic patients (Holi *et al.*, 2006; O’Leary *et al.*, 2007; Cima *et al.*, 2008), patients with antisocial disorder with limited empathy and guilt and constricted emotionality (Hawes *et al.*, 2009), and adolescents with conduct disorder (Cappadocia *et al.*, 2009; Victoroff, 2009).

Another hormone involved in aggressive behaviour is testosterone. High testosterone levels enhance attention to aggressive stimuli, downregulate the interaction between cognitive and emotional brain systems and are associated with dominant aggressive behaviour (Dabbs *et al.*, 1995; Dabbs and Hargrove, 1997). During moral decision-making, individuals having high testosterone levels are more likely to make utilitarian decisions, especially when doing so implies acts of aggression and social cost (Carney and Mason, 2010). Testosterone is also associated with diminished sensitivity to the affective signals that facilitate pursuit of empathic behaviours and choices (van Honk *et al.*, 2004, 2005, 2010). Although the gender factor is largely ignored in neuroimaging and lesional studies on morality, testosterone might partially explain the gender differences highlighted by previous behavioural studies (Gilligan, 1982; Jaffee and Hyde, 2000).

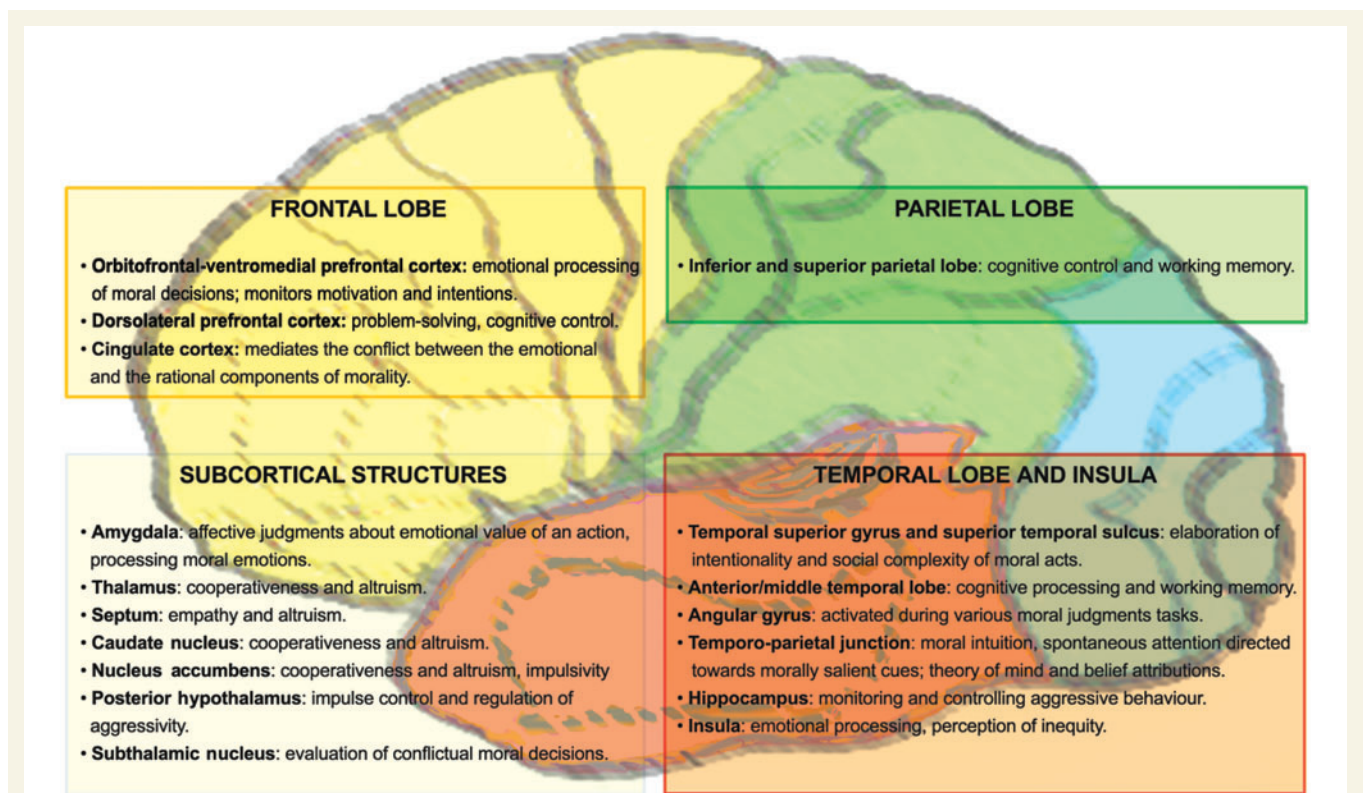
Finally, because a heightened testosterone level alone is often not enough to induce violence (Terburg *et al.*, 2009), the hormonal marker for aggressive behaviour is the testosterone/cortisol ratio. When high testosterone is combined with low cortisol,

aggression is unmanageable and the subject could become a danger to society (Terburg *et al.*, 2009; van Honk *et al.*, 2010).

We found no studies investigating the correlation between the performances in a moral task with either COMT/MAOA genetic polymorphism or testosterone/cortisol levels in healthy subjects, although this could be an interesting issue for future research. Another possible shortcoming worth investigating is that these studies measured basal hormone concentrations, without considering receptor site functioning, possible interactions with other hormones and the mechanisms that regulate protein transcription and hormone secretion, all factors that can ultimately influence the behavioural effects of a given hormone, independently from its concentrations (Carney and Mason, 2010).

## An overall view

As well as depending on the various underlying cortical areas, moral functions and abnormal moral behaviour depend on a distributed functional neural network connecting cortical and subcortical structures (Fig. 4 and Table 1), modulated by neurotransmitters and hormonal systems. Recent behavioural evidence showing abnormal moral reasoning in patients with callosotomy also suggest that this neural network is not confined to one side of the brain (Miller *et al.*, 2010). Because morality is a complex process, some of the brain structures involved share their neural circuits with those controlling other behavioural processes, such as



**Figure 4** A schematic diagram reporting the hypothetical role of various brain areas in regulating moral behaviour.

**Table 1** List of studies subdivided according to brain area and type of study

Brain structure	Evidence from	References
<b>Frontal lobe</b>		
Frontopolar cortex	Lesional studies	Eslinger <i>et al.</i> , 1992; Anderson <i>et al.</i> , 1999
Orbitofrontal cortex— ventromedial prefrontal cortex	Studies in healthy subjects	Rolls, 2000; Greene <i>et al.</i> , 2001; Moll <i>et al.</i> , 2001, 2002a, b, 2005; Heekeren <i>et al.</i> , 2003; Borg <i>et al.</i> , 2006; Harenski and Hamann, 2006; Luo <i>et al.</i> , 2006; Prehn <i>et al.</i> , 2008; Harenski <i>et al.</i> , 2009; Young and Saxe, 2009; Cooper <i>et al.</i> , 2010; Fumagalli <i>et al.</i> , 2010; Shenhav and Greene, 2010; Sommer <i>et al.</i> , 2010
	Psychopathy and antisocial behaviour	Goyer <i>et al.</i> , 1994; Raine <i>et al.</i> , 1994, 2000; Bufkin and Luttrell, 2005; Yang <i>et al.</i> , 2005; Harenski <i>et al.</i> , 2009, 2010
	Lesional studies	Damasio <i>et al.</i> , 1990; Saver and Damasio, 1991; Eslinger <i>et al.</i> , 1992; Rolls <i>et al.</i> , 1994; Grafman <i>et al.</i> , 1996; Anderson <i>et al.</i> , 1999; Brower and Price, 2001; Ciaramelli <i>et al.</i> , 2007; Koenigs <i>et al.</i> , 2007; Braun <i>et al.</i> , 2008; Feuchtwanger, 1923 (cited in David <i>et al.</i> , 2009); Moretto <i>et al.</i> , 2009; Thomas <i>et al.</i> , 2011; Young <i>et al.</i> , 2010b
	Frontotemporal dementia	Moll <i>et al.</i> , 2011
	Epilepsy	Woermann <i>et al.</i> , 2000
Dorsolateral prefrontal cortex	Studies in healthy subjects	Greene <i>et al.</i> , 2001, 2004; Haushofer and Fehr, 2008; Prehn <i>et al.</i> , 2008; Greene and Paxton, 2009
Cingulate cortex	Studies in healthy subjects	Greene <i>et al.</i> , 2001, 2004; Harenski <i>et al.</i> , 2008
<b>Temporal lobe</b>		
Temporal lobe	Lesional studies	David <i>et al.</i> , 2009
	Psychopathy and antisocial behaviour	Volkow and Tancredi, 1987; Amen <i>et al.</i> , 1996; Soderstrom <i>et al.</i> , 2000; Raine <i>et al.</i> , 2001; Dolan <i>et al.</i> , 2002; Kruesi <i>et al.</i> , 2004; Barkataki <i>et al.</i> , 2006; David <i>et al.</i> , 2009
	Epilepsy	Saint-Hilaire <i>et al.</i> , 1981
Anterior/middle temporal lobe	Studies in healthy subjects	Moll <i>et al.</i> , 2001; Heekeren <i>et al.</i> , 2003, 2005; Greene <i>et al.</i> , 2004; Harenski and Hamann, 2006; Sommer <i>et al.</i> , 2010
	Psychopathy and antisocial behaviour	Volkow <i>et al.</i> , 1995; Seidenwurm <i>et al.</i> , 1997; Wong <i>et al.</i> , 1997; Soderstrom <i>et al.</i> , 2000; Goethals <i>et al.</i> , 2005; Harenski <i>et al.</i> , 2010
	Epilepsy	Juhasz <i>et al.</i> , 2001
Superior temporal sulcus	Studies in healthy subjects	Moll <i>et al.</i> , 2001, 2002a, b; Heekeren <i>et al.</i> , 2003, 2005; Greene <i>et al.</i> , 2004; Borg <i>et al.</i> , 2006; Harenski and Hamann, 2006
Superior temporal gyrus	Psychopathy and antisocial behaviour	Kiehl <i>et al.</i> , 2004; Müller <i>et al.</i> , 2007 (cited in Weber <i>et al.</i> , 2008)
Temporo-parietal junction	Studies in healthy subjects	Young <i>et al.</i> , 2007, 2010a; Kedia <i>et al.</i> , 2008; Harenski <i>et al.</i> , 2009; Young and Saxe, 2009; Young and Dungan, 2011
Angular gyrus	Studies in healthy subjects	Greene <i>et al.</i> , 2001; Borg <i>et al.</i> , 2006
Insula	Studies in healthy subjects	Moll <i>et al.</i> , 2002b; Greene <i>et al.</i> , 2004; Borg <i>et al.</i> , 2008; Hsu <i>et al.</i> , 2008; Kedia <i>et al.</i> , 2008; Cooper <i>et al.</i> , 2010; Caceda <i>et al.</i> , 2011
	Psychopathy and antisocial behaviour	Birbaumer <i>et al.</i> , 2005; de Oliveira-Souza <i>et al.</i> , 2008
Hippocampus	Psychopathy and antisocial behaviour	Laakso <i>et al.</i> , 2001; Boccardi <i>et al.</i> , 2010
	Epilepsy	Saint-Hilaire <i>et al.</i> , 1981
<b>Parietal lobe</b>		
Parietal cortex	Psychopathy and antisocial behaviour	Soderstrom <i>et al.</i> , 2000
Inferior parietal lobe	Studies in healthy subjects	Greene <i>et al.</i> , 2001, 2004; Harenski <i>et al.</i> , 2008; Caceda <i>et al.</i> , 2011
Superior parietal cortex	Psychopathy and antisocial behaviour	Raine <i>et al.</i> , 1997; Siever <i>et al.</i> , 1999
<b>Subcortical structures</b>		
Amygdala	Studies in healthy subjects	Moll <i>et al.</i> , 2002b; Greene <i>et al.</i> , 2004; Heekeren <i>et al.</i> , 2005; Harenski and Hamann, 2006; Harenski <i>et al.</i> , 2008; Sommer <i>et al.</i> , 2010
	Psychopathy and antisocial behaviour	Wong <i>et al.</i> , 1997; Schneider <i>et al.</i> , 2000; Tiihonen <i>et al.</i> , 2000; Van Elst <i>et al.</i> , 2000; Kiehl <i>et al.</i> , 2001; Veit <i>et al.</i> , 2002; Müller <i>et al.</i> , 2003; Birbaumer <i>et al.</i> , 2005; Sterzer <i>et al.</i> , 2005; Yang <i>et al.</i> , 2006; Fountas and Smith, 2007; Glenn <i>et al.</i> , 2009; Harenski <i>et al.</i> , 2010
	Stimulation	Heath <i>et al.</i> , 1955; Treiman, 1991
Septum	Studies in healthy subjects	Moll <i>et al.</i> , 2006
	Frontotemporal dementia	Moll <i>et al.</i> , 2011
	Psychopathy and antisocial behaviour	Gorenstein and Newman, 1980
Caudate nucleus	Studies in healthy subjects	de Quervain <i>et al.</i> , 2004; Luo <i>et al.</i> , 2006; Harbaugh <i>et al.</i> , 2007
Nucleus accumbens	Psychopathy and antisocial behaviour	Buckholtz <i>et al.</i> , 2010
Subthalamic nucleus	Deep brain stimulation studies	Fumagalli <i>et al.</i> , 2011
Thalamus	Studies in healthy subjects	Sommer <i>et al.</i> , 2010
Posterior hypothalamus	Deep brain stimulation studies	Bejjani <i>et al.</i> , 2002; Sensi <i>et al.</i> , 2004; Franzini <i>et al.</i> , 2005; Hernando <i>et al.</i> , 2008; Kuhn <i>et al.</i> , 2008

emotions and theory of mind. Overall, findings from healthy subjects and patients show that the anatomical structures implicated in morality are the frontal and temporal cortices and specific subcortical structures. The frontal lobe, in particular the orbital and ventromedial prefrontal cortices, has a primary role in moral behaviour, emotionally driving moral decisions and being involved in abnormal moral behaviour. The temporal lobe intervenes in moral decisions through its role in intentionality and social complexity of moral decisions (superior temporal sulcus), belief attributions and theory of mind (temporo-parietal junction), and is often associated with aggressive behaviour in violent patients and criminals. Among subcortical structures, the amygdala is of major importance in processing moral emotions and when damaged or dysfunctional, leads to violence. Finally, subcortical involvement in abnormal moral behaviour might advance research on the therapeutic effects of deep brain stimulation in psychopathy and violent behaviour.

## Limitations

Moral neuroscience is an extremely wide and rapidly expanding field. In this review, we synthetically outline only the major research findings. Despite this limitation, our review should provide to the clinical neuroscientist a useful tool for approaching the complex biology of moral behaviour.

Among limitations to keep in mind in planning further experimental work, an initial problem is that the widely varying tasks used for assessing morality make the various results difficult to compare. Moral tasks also have intrinsic limitations. For example, most tasks fail to take an ecological approach (the items proposed poorly reflect environmental and daily experience). Some tasks also require subjects to evaluate abstract judgements excluding the complex context in which the decision has to be taken. Third, task instructions tell the subject not to make additional assumptions not included in the text, even though problem-solving is a faculty that automatically intervenes in these situations. And, equally important, moral items distinctly differ one from the other and involve various moral rules, values (honesty, money, life, health, probity, solidarity) and violations.

Another limitation concerns the failure to balance the study sample for gender. Gender is a major problem that studies on morality need to take into account (Harenski *et al.*, 2008; Fumagalli *et al.*, 2010). Studies on patients often enrol too few subjects, usually owing to the strict diagnostic criteria required to select those with a disease or brain lesion. Studies on patients with lesions also need careful interpretation owing to the remarkable heterogeneity (volume, shape, date of onset, concurrent treatments) in spontaneous lesions. This heterogeneity can sometimes make it difficult to pool data from different patients. Finally, because morality is a complex process, influenced by social and cultural factors, future studies should also consider age, education and religious beliefs.

## Concluding remarks

The findings our review provides on the functional and clinical neuroanatomy of morality argue strongly that a brain network for moral behaviour exists. As well as investigating the brain

areas and circuits mediating normal and abnormal moral behaviour, future research, taking into consideration the foregoing limitations, should aim to find out how human moral behaviour is influenced by genetic, endocrine, environmental and cultural factors.

Understanding the 'moral brain' and its behavioural counterpart raises several potentially important legal and clinical implications. Ruling that criminals whose abnormal moral behaviour depends on biological anomalies cannot be held fully responsible for their criminal actions, an Italian court lightened a sentence for a convicted murderer because tests identified genes linked to violent behaviour (Feresin, 2009). The enormous advances neurosciences have achieved over the past decades should therefore help to update the criteria and protocols for deciding whether the criminal brain is normal. Forensic neurosciences now have major importance (Bianchi *et al.*, 2009) and neurologists could have increasing weight as court advisors.

From a clinical point of view, subjects manifesting abnormal moral behaviour should be screened for neurological disorders to promote an early diagnosis. A potentially important issue arises when clinicians treat patients whose social position makes them responsible for others (including state leaders and politicians) with abnormalities of moral behaviour or with other conditions (or treatment) that could influence their 'moral brain'. In these cases, an early diagnosis and, whenever possible, effective treatment are important both for the patient and for the welfare of society. Highlighting the social importance of early diagnosis and treatment, David Owen (2008) described in his book 'In Sickness and in Power' several cases of leaders responsible for states and nations who took important political decisions whilst suffering from various medical conditions and discussed how the disease or drugs taken could have influenced the decision itself possibly even in its moral aspects. Hence, recognizing acquired abnormalities in moral decision-making raises intriguing concerns in clinical practice. For instance, should moral reasoning be formally evaluated after a minor stroke without overt cognitive and motor sequelae, or during any medical treatment with drugs acting on the brain? Last, understanding the dysfunctional brain structures underlying abnormal moral behaviour can lead to specific treatments nowadays using deep brain stimulation or other new non-invasive neuromodulation techniques. For instance, apart from treating aggression, deep brain stimulation might be used in other forms of pathological antisocial behaviour or violence (including sexual assaulters and paedophiles) when education and rehabilitation programmes or other treatments fail. Among future concerns about the hypothetical use of brain stimulation techniques in this field, the possibility of shaping individual morality raises intriguing ethical issues that should prompt the development of treatment guidelines.

## Acknowledgements

The authors wish to thank Mrs Alice Crossman for linguistic and editorial advice. We deeply acknowledge the noteworthy contribution and thoughtful anonymous comments of the reviewer.

## Funding

Università degli Studi di Milano and Fondazione IRCCS Ca' Granda, Ospedale Maggiore Policlinico, Milano, Italy.

## References

- Accornero N, Li Voti P, La Riccia M, Gregori B. Visual evoked potentials modulation during direct current cortical polarization. *Exp Brain Res* 2007; 178: 261–6.
- Amen DG, Stubblefield M, Carmicheal B, Thisted R. Brain SPECT findings and aggressiveness. *Ann Clin Psychiatry* 1996; 8: 129–37.
- Anderson SW, Bechara A, Damasio H, Tranel D, Damasio AR. Impairment of social and moral behavior related to early damage in human prefrontal cortex. *Nat Neurosci* 1999; 2: 1032–7.
- Bar-On R, Tranel D, Denburg NL, Bechara A. Exploring the neurological substrate of emotional and social intelligence. *Brain* 2003; 126: 1790–800.
- Barkataki I, Kumari V, Das M, Taylor P, Sharma T. Volumetric structural brain abnormalities in men with schizophrenia or antisocial personality disorder. *Behav Brain Res* 2006; 169: 239–47.
- Baron RA, Richardson DR. *Human Aggression*. New York: Plenum Press; 2004.
- Bejjani BP, Houeto JL, Hariz M, Yelnik J, Mesnage V, Bonnet AM, et al. Aggressive behavior induced by intraoperative stimulation in the triangle of Sano. *Neurology* 2002; 59: 1425–7.
- Berrios GE. The origins of psychosurgery: Shaw, Burckhardt and Moniz. *Hist Psychiatry* 1997; 8: 61–81.
- Bianchi A, Gulotta G, Sartori G. *Manuale di neuroscienze forensi*. Milano: Giuffrè; 2009.
- Birbaumer N, Veit R, Lotze M, Erb M, Hermann C, Grodd W, et al. Deficient fear conditioning in psychopathy: a functional magnetic resonance imaging study. *Arch Gen Psychiatry* 2005; 62: 799–805.
- Blair RJ. The amygdala and ventromedial prefrontal cortex in morality and psychopathy. *Trends Cogn Sci* 2007; 11: 387–92.
- Boccardi M, Ganzola R, Rossi R, Sabbatoli F, Laakso MP, Repo-Tiihonen E, et al. Abnormal hippocampal shape in offenders with psychopathy. *Hum Brain Mapp* 2010; 31: 438–47.
- Borg JS, Hynes C, Van Horn J, Grafton S, Sinnott-Armstrong W. Consequences, action, and intention as factors in moral judgments: an fMRI investigation. *J Cogn Neurosci* 2006; 18: 803–17.
- Borg JS, Lieberman D, Kiehl KA. Infection, incest, and iniquity: investigating the neural correlates of disgust and morality. *J Cogn Neurosci* 2008; 20: 1529–46.
- Braun CM, Leveille C, Guimond A. An orbitofrontostriatopallidal pathway for morality: evidence from postlesion antisocial and obsessive-compulsive disorder. *Cogn Neuropsychiatry* 2008; 13: 296–337.
- Brower MC, Price BH. Neuropsychiatry of frontal lobe dysfunction in violent and criminal behaviour: a critical review. *J Neurol Neurosurg Psychiatry* 2001; 71: 720–6.
- Brucke C, Kupsch A, Schneider GH, Hariz MI, Nuttin B, Kopp U, et al. The subthalamic region is activated during valence-related emotional processing in patients with Parkinson's disease. *Eur J Neurosci* 2007; 26: 767–74.
- Brunner HG, Nelen M, Breakefield XO, Ropers HH, van Oost BA. Abnormal behavior associated with a point mutation in the structural gene for monoamine oxidase A. *Science* 1993; 262: 578–80.
- Buckholtz JW, Treadway MT, Cowan RL, Woodward ND, Benning SD, Li R, et al. Mesolimbic dopamine reward system hypersensitivity in individuals with psychopathic traits. *Nat Neurosci* 2010; 13: 419–21.
- Bucklin JL, Luttrell VR. Neuroimaging studies of aggressive and violent behavior: current findings and implications for criminology and criminal justice. *Trauma Violence Abuse* 2005; 6: 176–91.
- Burman MA, Starr MJ, Gewirtz JC. Dissociable effects of hippocampus lesions on expression of fear and trace fear conditioning memories in rats. *Hippocampus* 2006; 16: 103–13.
- Butter CM, Snyder DR, McDonald JA. Effects of orbital frontal lesions on aversive and aggressive behaviors in rhesus monkeys. *J Comp Physiol Psychol* 1970; 72: 132–44.
- Caceda R, James GA, Ely TD, Snarey J, Kilts CD. Mode of effective connectivity within a putative neural network differentiates moral cognitions related to care and justice ethics. *PLoS One* 2011; 6: e14730.
- Cappadocia MC, Desrocher M, Pepler D, Schroeder JH. Contextualizing the neurobiology of conduct disorder in an emotion dysregulation framework. *Clin Psychol Rev* 2009; 29: 506–18.
- Cardinal RN. Neural systems implicated in delayed and probabilistic reinforcement. *Neural Netw* 2006; 19: 1277–301.
- Carney DR, Mason MF. Decision making and testosterone: when the ends justify the means. *J Exp Soc Psychol* 2010; 46: 668–71.
- Caspi A, McClay J, Moffitt TE, Mill J, Martin J, Craig IW, et al. Role of genotype in the cycle of violence in maltreated children. *Science* 2002; 297: 851–4.
- Ciamarelli E, Muccioli M, Ladavas E, di Pellegrino G. Selective deficit in personal moral judgment following damage to ventromedial prefrontal cortex. *Soc Cogn Affect Neurosci* 2007; 2: 84–92.
- Cima M, Smeets T, Jelicic M. Self-reported trauma, cortisol levels, and aggression in psychopathic and non-psychopathic prison inmates. *Biol Psychol* 2008; 78: 75–86.
- Cooper JC, Krepes TA, Wiebe T, Pirkl T, Knutson B. When giving is good: ventromedial prefrontal cortex activation for others' intentions. *Neuron* 2010; 67: 511–21.
- Craig IW, Halton KE. Genetics of human aggressive behaviour. *Hum Genet* 2009; 126: 101–13.
- Dabbs JM, Carr TS, Frady RL, Riad JK. Testosterone, crime, and misbehavior among 692 male prison inmates. *Personal Individ Diff* 1995; 9: 269–75.
- Dabbs JM Jr, Hargrove MF. Age, testosterone, and behavior among female prison inmates. *Psychosom Med* 1997; 59: 477–80.
- Damasio A. *Descartes' error*. New York: Putnam; 1994.
- Damasio AR, Tranel D, Damasio H. Individuals with sociopathic behavior caused by frontal damage fail to respond autonomically to social stimuli. *Behav Brain Res* 1990; 41: 81–94.
- David A, Fleminger S, Kopelman M, Lovestone S, Mellers J. *Lishman's Organic Psychiatry: A Textbook of Neuropsychiatry*. Wiley-Blackwell; 2009.
- de Oliveira-Souza R, Hare RD, Bramati IE, Garrido GJ, Azevedo Ignacio F, Tovar-Moll F, et al. Psychopathy as a disorder of the moral brain: fronto-temporo-limbic grey matter reductions demonstrated by voxel-based morphometry. *Neuroimage* 2008; 40: 1202–13.
- de Quervain DJ, Fischbacher U, Treyer V, Schellhammer M, Schnyder U, Buck A, et al. The neural basis of altruistic punishment. *Science* 2004; 305: 1254–8.
- Deakin JF. Depression and antisocial personality disorder: two contrasting disorders of 5HT function. *J Neural Trans Suppl* 2003; 64: 79–93.
- Devinsky O, Morrell MJ, Vogt BA. Contributions of anterior cingulate cortex to behaviour. *Brain* 1995; 118 (Pt 1): 279–306.
- Dolan MC, Deakin JFW, Roberts N, Anderson IM. Quantitative frontal and temporal structural MRI studies in personality-disordered offenders and control subjects. *Psychiatry Res Neuroimaging* 2002; 116: 133–49.
- Eisenberger NI, Taylor SE, Gable SL, Hilmert CJ, Lieberman MD. Neural pathways link social support to attenuated neuroendocrine stress responses. *Neuroimage* 2007; 35: 1601–12.
- Elliott FA. Neurology of aggression and episodic dyscontrol. *Semin Neurol* 1990; 10: 303–12.
- Eslinger PJ, Grattan LM, Damasio H, Damasio AR. Developmental consequences of childhood frontal lobe damage. *Arch Neurol* 1992; 49: 764–9.
- Fabian JM. Neuropsychological and neurological correlates in violent and homicidal offenders: a legal and neuroscience perspective. *Aggress Violent Behav* 2010; 15: 209–23.

- Feldman RP, Goodrich JT. Psychosurgery: a historical overview. *Neurosurgery* 2001; 48: 647–59.
- Feresin E. Lighter sentence for murderer with 'bad genes'. *Nat News* 2009; <http://www.nature.com/news/2009/091030/full/news.2009.1050.html> (30 October 2009, date last accessed).
- Fountas KN, Smith JR. Historical evolution of stereotactic amygdalotomy for the management of severe aggression. *J Neurosurg* 2007; 106: 710–3.
- Fox D. Neuroscience: Brain buzz. *Nature* 2011; 472: 156–8.
- Franzini A, Marras C, Ferroli P, Bugiani O, Broggi G. Stimulation of the posterior hypothalamus for medically intractable impulsive and violent behavior. *Stereotact Funct Neurosurg* 2005; 83: 63–6.
- Freeman W. Psychosurgery. *J Nat Med Assoc* 1950; 42: 206–9.
- Fumagalli M, Giannicola G, Rosa M, Marceglia S, Lucchiarri C, Mrakic-Spota S, et al. Conflict-dependent dynamic of subthalamic nucleus oscillations during moral decisions. *Soc Neurosci* 2011; 6: 243–56.
- Fumagalli M, Vergari M, Pasqualetti P, Marceglia S, Mameli F, Ferrucci R, et al. Brain switches utilitarian behavior: does gender make the difference? *PLoS One* 2010; 5: e8865.
- Funk CM, Gazzaniga MS. The functional brain architecture of human morality. *Curr Opin Neurobiol* 2009; 19: 678–81.
- Gilligan C. In a different voice: psychological theory and women's development. Cambridge: Harvard University Press; 1982.
- Glenn AL, Raine A, Schug RA. The neural correlates of moral decision-making in psychopathy. *Mol Psychiatry* 2009; 14: 5–6.
- Goethals I, Audenaert K, Jacobs F, Van den Eynde F, Bernagie K, Kolindou A, et al. Brain perfusion SPECT in impulsivity-related personality disorders. *Behav Brain Res* 2005; 157: 187–92.
- Gogos JA, Morgan M, Luine V, Santha M, Ogawa S, Pfaff D, et al. Catechol-O-methyltransferase-deficient mice exhibit sexually dimorphic changes in catecholamine levels and behavior. *Proc Natl Acad Sci USA* 1998; 95: 9991–6.
- Gorenstein EE, Newman JP. Disinhibitory psychopathology: a new perspective and a model for research. *Psychol Rev* 1980; 87: 301–15.
- Goyer PF, Andreason PJ, Semple WE, Clayton AH, King AC, Compton-Toth BA, et al. Positron-emission tomography and personality disorders. *Neuropsychopharmacology* 1994; 10: 21–8.
- Grafman J, Schwab K, Warden D, Pridgen A, Brown HR, Salazar AM. Frontal lobe injuries, violence, and aggression: a report of the Vietnam Head Injury Study. *Neurology* 1996; 46: 1231–8.
- Greene JD. Why are VMPFC patients more utilitarian? A dual-process theory of moral judgment explains. *Trends Cogn Sci* 2007; 11: 322–3; author reply 323–4.
- Greene JD, Morelli SA, Lowenberg K, Nystrom LE, Cohen JD. Cognitive load selectively interferes with utilitarian moral judgment. *Cognition* 2008; 107: 1144–54.
- Greene JD, Nystrom LE, Engell AD, Darley JM, Cohen JD. The neural bases of cognitive conflict and control in moral judgment. *Neuron* 2004; 44: 389–400.
- Greene JD, Paxton JM. Patterns of neural activity associated with honest and dishonest moral decisions. *Proc Natl Acad Sci USA* 2009; 106: 12506–11.
- Greene JD, Sommerville RB, Nystrom LE, Darley JM, Cohen JD. An fMRI investigation of emotional engagement in moral judgment. *Science* 2001; 293: 2105–8.
- Guillot PV, Roubertoux PL, Crusio WE. Hippocampal mossy fiber distributions and intermale aggression in seven inbred mouse strains. *Brain Res* 1994; 660: 167–9.
- Gunter TD, Vaughn MG, Philibert RA. Behavioral genetics in antisocial spectrum disorders and psychopathy: a review of the recent literature. *Behav Sci Law* 2010; 28: 148–73.
- Hamberger MJ, Drake EB. Cognitive functioning following epilepsy surgery. *Curr Neurol Neurosci Rep* 2006; 6: 319–26.
- Harbaugh WT, Mayr U, Burghart DR. Neural responses to taxation and voluntary giving reveal motives for charitable donations. *Science* 2007; 316: 1622–5.
- Harenski CL, Antonenko O, Shane MS, Kiehl KA. Gender differences in neural mechanisms underlying moral sensitivity. *Soc Cogn Affect Neurosci* 2008; 3: 313–21.
- Harenski CL, Hamann S. Neural correlates of regulating negative emotions related to moral violations. *Neuroimage* 2006; 30: 313–24.
- Harenski CL, Harenski KA, Shane MS, Kiehl KA. Aberrant neural processing of moral violations in criminal psychopaths. *J Abnorm Psychol* 2010; 119: 863–74.
- Harenski CL, Kim SH, Hamann S. Neuroticism and psychopathy predict brain activation during moral and nonmoral emotion regulation. *Cogn Affect Behav Neurosci* 2009; 9: 1–15.
- Haushofer J, Fehr E. You shouldn't have: your brain on others' crimes. *Neuron* 2008; 60: 738–40.
- Hawes DJ, Brennan J, Dadds MR. Cortisol, callous-unemotional traits, and pathways to antisocial behavior. *Curr Opin Psychiatry* 2009; 22: 357–62.
- Heath RG. Correlation of brain activity with emotion: a basis for developing treatment of violent-aggressive behavior. *J Am Acad Psychoanal* 1992; 20: 335–46.
- Heath RG, Monroe RR, Mockle WA. Stimulation of the amygdaloid nucleus in a schizophrenic patient. *Amer J Psychiat* 1955; 111: 862–3.
- Heekeren HR, Wartenburger I, Schmidt H, Prehn K, Schwintowski HP, Villringer A. Influence of bodily harm on neural correlates of semantic and moral decision-making. *Neuroimage* 2005; 24: 887–97.
- Heekeren HR, Wartenburger I, Schmidt H, Schwintowski HP, Villringer A. An fMRI study of simple ethical decision-making. *Neuroreport* 2003; 14: 1215–9.
- Heller AC, Amar AP, Liu CY, Apuzzo ML. Surgery of the mind and mood: a mosaic of issues in time and evolution. *Neurosurgery* 2006; 59: 720–39.
- Hernando V, Pastor J, Pedrosa M, Pena E, Sola RG. Low-frequency bilateral hypothalamic stimulation for treatment of drug-resistant aggressiveness in a young man with mental retardation. *Stereotact Funct Neurosurg* 2008; 86: 219–23.
- Holi M, Auvinen-Lintunen L, Lindberg N, Tani P, Virkkunen M. Inverse correlation between severity of psychopathic traits and serum cortisol levels in young adult violent male offenders. *Psychopathology* 2006; 39: 102–4.
- Hsu M, Anen C, Quartz SR. The right and the good: distributive justice and neural encoding of equity and efficiency. *Science* 2008; 320: 1092–5.
- Huebner B, Dwyer S, Hauser M. The role of emotion in moral psychology. *Trends Cogn Sci* 2009; 13: 1–6.
- Jaffee S, Hyde JS. Gender differences in moral orientation: a meta-analysis. *Psychol Bull* 2000; 126: 703–26.
- Juhasz C, Behen ME, Muzik O, Chugani DC, Chugani HT. Bilateral medial prefrontal and temporal neocortical hypometabolism in children with epilepsy and aggression. *Epilepsia* 2001; 42: 991–1001.
- Kedia G, Berthoz S, Wessa M, Hilton D, Martinot JL. An agent harms a victim: a functional magnetic resonance imaging study on specific moral emotions. *J Cogn Neurosci* 2008; 20: 1788–98.
- Kiehl KA, Smith AM, Hare RD, Mendrek A, Forster BB, Brink J, et al. Limbic abnormalities in affective processing by criminal psychopaths as revealed by functional magnetic resonance imaging. *Biol Psychiatry* 2001; 50: 677–84.
- Kiehl KA, Smith AM, Mendrek A, Forster BB, Hare RD, Liddle PF. Temporal lobe abnormalities in semantic processing by criminal psychopaths as revealed by functional magnetic resonance imaging. *Psychiatry Res* 2004; 130: 297–312.
- Knight GC. Bi-frontal stereotactic tractotomy: an atraumatic operation of value in the treatment of intractable psychoneurosis. *Br J Psychiatry* 1969; 115: 257–66.
- Koenigs M, Ukeberuwa D, Campion P, Grafman J, Wassermann E. Bilateral frontal transcranial direct current stimulation: failure to replicate classic findings in healthy subjects. *Clin Neurophysiol* 2009; 120: 80–4.

- Koenigs M, Young L, Adolphs R, Tranel D, Cushman F, Hauser M, et al. Damage to the prefrontal cortex increases utilitarian moral judgments. *Nature* 2007; 446: 908–11.
- Kruesi MJ, Casanova MF, Mannheim G, Johnson-Bilder A. Reduced temporal lobe volume in early onset conduct disorder. *Psychiatry Res* 2004; 132: 1–11.
- Kuhn AA, Hariz MI, Silberstein P, Tisch S, Kupsch A, Schneider GH, et al. Activation of the subthalamic region during emotional processing in Parkinson disease. *Neurology* 2005; 65: 707–13.
- Kuhn J, Lenartz D, Mai JK, Huff W, Klosterkoetter J, Sturm V. Disappearance of self-aggressive behavior in a brain-injured patient after deep brain stimulation of the hypothalamus: technical case report. *Neurosurgery* 2008; 62: E1182.
- Laakso MP, Vaurio O, Koivisto E, Savolainen L, Eronen M, Aronen HJ, et al. Psychopathy and the posterior hippocampus. *Behav Brain Res* 2001; 118: 187–93.
- Luo Q, Nakic M, Wheatley T, Richell R, Martin A, Blair RJ. The neural basis of implicit moral attitude—an IAT study using event-related fMRI. *Neuroimage* 2006; 30: 1449–57.
- Mameli F, Mrakic-Spota S, Vergari M, Fumagalli M, Macis M, Ferrucci R, et al. Dorsolateral prefrontal cortex specifically processes general – but not personal – knowledge deception: Multiple brain networks for lying. *Behav Brain Res* 2010; 211: 164–8.
- Marceglia S, Fiorio M, Foffani G, Mrakic-Spota S, Tiriticco M, Locatelli M, et al. Modulation of beta oscillations in the subthalamic area during action observation in Parkinson's disease. *Neuroscience* 2009; 161: 1027–36.
- Marceglia S, Fumagalli M, Priori A. What neurophysiological recordings tell us about cognitive and behavioral functions of the human subthalamic nucleus. *Expert Rev Neurother* 2011; 11: 139–49.
- McDermott R, Tingley D, Cowden J, Frazzetto G, Johnson DD. Monoamine oxidase A gene (MAOA) predicts behavioral aggression following provocation. *Proc Natl Acad Sci USA* 2009; 106: 2118–23.
- Meyer-Lindenberg A, Buckholtz JW, Kolachana B, A RH, Pezawas L, Blasi G, et al. Neural mechanisms of genetic risk for impulsivity and violence in humans. *Proc Natl Acad Sci USA* 2006; 103: 6269–74.
- Miller MB, Sinnott-Armstrong W, Young L, King D, Paggi A, Fabri M, et al. Abnormal moral reasoning in complete and partial callosotomy patients. *Neuropsychologia* 2010; 48: 2215–20.
- Moll J, de Oliveira-Souza R, Bramati IE, Grafman J. Functional networks in emotional moral and nonmoral social judgments. *Neuroimage* 2002a; 16: 696–703.
- Moll J, de Oliveira-Souza R, Eslinger PJ, Bramati IE, Mourao-Miranda J, Andreiuolo PA, et al. The neural correlates of moral sensitivity: a functional magnetic resonance imaging investigation of basic and moral emotions. *J Neurosci* 2002b; 22: 2730–6.
- Moll J, Eslinger PJ, Oliveira-Souza R. Frontopolar and anterior temporal cortex activation in a moral judgment task: preliminary functional MRI results in normal subjects. *Arq Neuropsiquiatr* 2001; 59: 657–64.
- Moll J, Krueger F, Zahn R, Pardini M, de Oliveira-Souza R, Grafman J. Human fronto-mesolimbic networks guide decisions about charitable donation. *Proc Natl Acad Sci USA* 2006; 103: 15623–8.
- Moll J, Schulkin J. Social attachment and aversion in human moral cognition. *Neurosci Biobehav Rev* 2009; 33: 456–65.
- Moll J, Zahn R, de Oliveira-Souza R, Bramati IE, Krueger F, Tura B, et al. Impairment of prosocial sentiments is associated with frontopolar and septal damage in frontotemporal dementia. *Neuroimage* 2011; 54: 1735–42.
- Moll J, Zahn R, de Oliveira-Souza R, Krueger F, Grafman J. Opinion: the neural basis of human moral cognition. *Nat Rev Neurosci* 2005; 6: 799–809.
- Moniz E. Prefrontal leucotomy in the treatment of mental disorders. *Am J Psychiatry* 1937; 93: 1379–85.
- Moretto G, Ladavas E, Mattioli F, di Pellegrino G. A psychophysiological investigation of moral judgment after ventromedial prefrontal damage. *J Cogn Neurosci* 2009; 22: 1888–99.
- Müller JL, Sommer M, Wagner V, Lange K, Taschler H, Röder CH, et al. Abnormalities in emotion processing within cortical and subcortical regions in criminal psychopaths: evidence from a functional magnetic resonance imaging study using pictures with emotional content. *Biol Psychiatry* 2003; 54: 152–62.
- O'Leary MM, Loney BR, Eckel LA. Gender differences in the association between psychopathic personality traits and cortisol response to induced stress. *Psychoneuroendocrinology* 2007; 32: 183–91.
- Owen D. In sickness and in power: illness in heads of government during the last 100 years. London: Methuen Publishing Ltd; 2008.
- Pietrini P, Bambini V. Homo ferrox: the contribution of functional brain studies to understanding the neural bases of aggressive and criminal behavior. *Int J Law Psychiatry* 2009; 32: 259–65.
- Prehn K, Wartenburger I, Meriau K, Scheibe C, Goodenough OR, Villringer A, et al. Individual differences in moral judgment competence influence neural correlates of socio-normative judgments. *Soc Cogn Affect Neurosci* 2008; 3: 33–46.
- Priori H, Schwegler H, Marashi V, Sachser N. Exploration, emotionality, and hippocampal mossy fibers in nonaggressive AB/Gat and congenic highly aggressive mice. *Hippocampus* 2004; 14: 135–40.
- Priori A. Brain polarization in humans: a reappraisal of an old tool for prolonged non-invasive modulation of brain excitability. *Clin Neurophysiol* 2003; 114: 589–95.
- Priori A, Mameli F, Cogiamanian F, Marceglia S, Tiriticco M, Mrakic-Spota S, et al. Lie-specific involvement of dorsolateral prefrontal cortex in deception. *Cereb Cortex* 2008; 18: 451–5.
- Raine A, Buchsbaum M, LaCasse L. Brain abnormalities in murderers indicated by positron emission tomography. *Biol Psychiatry* 1997; 42: 495–508.
- Raine A, Buchsbaum MS, Stanley J, Lottenberg S, Abel L, Stoddard J. Selective reductions in prefrontal glucose metabolism in murderers. *Biol Psychiatry* 1994; 36: 365–73.
- Raine A, Lencz T, Bihle S, LaCasse L, Colletti P. Reduced prefrontal gray matter volume and reduced autonomic activity in antisocial personality disorder. *Arch Gen Psychiatry* 2000; 57: 119–27.
- Raine A, Park S, Lencz T, Bihle S, LaCasse L, Widom CS, et al. Reduced right hemisphere activation in severely abused violent offenders during a working memory task: an fMRI study. *Aggress Behav* 2001; 27: 111–29.
- Raine A, Yang Y. Neural foundations to moral reasoning and antisocial behavior. *Soc Cogn Affect Neurosci* 2006; 1: 203–13.
- Rolls ET. The orbitofrontal cortex and reward. *Cereb Cortex* 2000; 10: 284–94.
- Rolls ET, Hornak J, Wade D, McGrath J. Emotion-related learning in patients with social and emotional changes associated with frontal lobe damage. *J Neurol Neurosurg Psychiatry* 1994; 57: 1518–24.
- Rush JA, First MB, Blacker D. *Handbook of Psychiatric Measures*. Washington, D.C: American Psychiatric Publishing; 2008.
- Saint-Hilaire JM, Gilbert M, Bouvier G, Barbeau A. [Epilepsy with aggressive behavior. Two cases with depth-electrodes recordings (author's transl)]. *Rev Neurol* 1981; 137: 161–79.
- Saver JL, Damasio AR. Preserved access and processing of social knowledge in a patient with acquired sociopathy due to ventromedial frontal damage. *Neuropsychologia* 1991; 29: 1241–9.
- Schneider F, Habel U, Kessler C, Posse S, Grodd W, Müller-Gärtner HW. Functional imaging of conditioned aversive emotional responses in antisocial personality disorder. *Neuropsychobiology* 2000; 42: 192–201.
- Schramm J. Temporal lobe epilepsy surgery and the quest for optimal extent of resection: a review. *Epilepsia* 2008; 49: 1296–307.
- Seidenwurm D, Pounds TR, Globus A, Valk PE. Abnormal temporal lobe metabolism in violent subjects: correlation of imaging and neuropsychiatric findings. *AJNR Am J Neuroradiol* 1997; 18: 625–31.
- Sensi M, Eleopra R, Cavallo MA, Sette E, Milani P, Quatralo R, et al. Explosive-aggressive behavior related to bilateral subthalamic stimulation. *Parkinsonism Relat Disord* 2004; 10: 247–51.
- Shenhav A, Greene JD. Moral judgments recruit domain-general valuation mechanisms to integrate representations of probability and magnitude. *Neuron* 2010; 67: 667–77.

- Shih JC, Chen K, Ridd MJ. Monoamine oxidase: from genes to behavior. *Annu Rev Neurosci* 1999; 22: 197–217.
- Shirtcliff EA, Vitacco MJ, Graf AR, Gostisha AJ, Merz JL, Zahn-Waxler C. Neurobiology of empathy and callousness: implications for the development of antisocial behavior. *Behav Sci Law* 2009; 27: 137–71.
- Siever LJ, Buchsbaum MS, New AS, Spiegel-Cohen J, Wei T, Hazlett EA, et al. d,l-Fenfluramine response in impulsive personality disorder assessed with [18F]fluorodeoxyglucose positron emission tomography. *Neuropsychopharmacology* 1999; 20: 413–23.
- Sluyter F, van Oortmerssen GA, de Ruiter AJ, Koolhaas JM. Aggression in wild house mice: current state of affairs. *Behav Genet* 1996; 26: 489–96.
- Soderstrom H, Tullberg M, Wikkelso C, Ekholm S, Forsman A. Reduced regional cerebral blood flow in non-psychotic violent offenders. *Psychiatry Res* 2000; 98: 29–41.
- Sommer M, Rothmayr C, Döhnel K, Meinhardt J, Schwerdtner J, Sodani B, et al. How should I decide? The neural correlates of everyday moral reasoning. *Neuropsychologia* 2010; 48: 2018–26.
- Sterzer P. Born to be criminal? What to make of early biological risk factors for criminal behavior. *Am J Psychiatry* 2010; 167: 1–3.
- Sterzer P, Stadler C, Krebs A, Kleinschmidt A, Poustka F. Abnormal neural responses to emotional visual stimuli in adolescents with conduct disorder. *Biol Psychiatry* 2005; 57: 7–15.
- Temel Y, Blokland A, Steinbusch HW, Visser-Vandewalle V. The functional role of the subthalamic nucleus in cognitive and limbic circuits. *Prog Neurobiol* 2005; 76: 393–413.
- Terburg D, Morgan B, van Honk J. The testosterone-cortisol ratio: a hormonal marker for proneness to social aggression. *Int J Law Psychiatry* 2009; 32: 216–23.
- Thomas BC, Croft KE, Tranel D. Harming kin to save strangers: further evidence for abnormally utilitarian moral judgments after ventromedial prefrontal damage. *J Cogn Neurosci* 2011; 23: 2186–96.
- Tiihonen J, Hodgins S, Vaurio O, Laakso M, Repo E, Soininen H, et al. Amygdaloid volume loss in psychopathy. *Neuroscience Meeting Planner*. New Orleans, LA: Society for Neuroscience; 2000.
- Treiman DM. Psychobiology of ictal aggression. *Adv Neurol* 1991; 55: 341–56.
- Tsetsenis T, Ma XH, Lo Iacono L, Beck SG, Gross C. Suppression of conditioning to ambiguous cues by pharmacogenetic inhibition of the dentate gyrus. *Nat Neurosci* 2007; 10: 896–902.
- Utz KS, Dimova V, Oppenlander K, Kerkhoff G. Electrified minds: transcranial direct current stimulation (tDCS) and galvanic vestibular stimulation (GVS) as methods of non-invasive brain stimulation in neuropsychology—a review of current data and future implications. *Neuropsychologia* 2010; 48: 2789–810.
- Van Elst LT, Woemann FG, Lemieux L, Thompson PJ, Trimble MR. Affective aggression in patients with temporal lobe epilepsy: a quantitative MRI study of the amygdala. *Brain* 2000; 123: 234–43.
- van Goozen SH, Fairchild G. Neuroendocrine and neurotransmitter correlates in children with antisocial behavior. *Horm Behav* 2006; 647–54.
- van Honk J, Harmon-Jones E, Morgan BE, Schutter DJ. Socially explosive minds: the triple imbalance hypothesis of reactive aggression. *J Pers* 2010; 78: 67–94.
- van Honk J, Peper JS, Schutter DJ. Testosterone reduces unconscious fear but not consciously experienced anxiety: implications for the disorders of fear and anxiety. *Biol Psychiatry* 2005; 58: 218–25.
- van Honk J, Schutter DJ. Unmasking feigned sanity: a neurobiological model of emotion processing in primary psychopathy. *Cogn Neuropsychiatry* 2006; 11: 285–306.
- van Honk J, Schutter D, Hermans E, Putman P, Tuiten A, Koppeschaar H. Testosterone shifts the balance between sensitivity for punishment and reward in healthy young women. *Psychoneuroendocrinology* 2004; 29: 937–43.
- Veit R, Flor H, Erb M, Hermann C, Lotze M, Grodd W, et al. Brain circuits involved in emotional learning in antisocial behavior and social phobia in humans. *Neurosci Lett* 2002; 328: 233–6.
- Victoroff J. Human aggression. In: Sadock BJ, Sadock VA, editors. *Kaplan and Sadock's Comprehensive Textbook of Psychiatry*. Philadelphia: Lippincott Williams and Wilkins; 2009.
- Volavka J, Bilder R, Nolan K. Catecholamines and aggression: the role of COMT and MAO polymorphisms. *Ann NY Acad Sci* 2004; 1036: 393–8.
- Volkow ND, Tancredi L. Neural substrates of violent behaviour. A preliminary study with positron emission tomography. *Br J Psychiatry* 1987; 151: 668–73.
- Volkow ND, Tancredi LR, Grant C, Gillespie H, Valentine A, Mullani N, et al. Brain glucose metabolism in violent psychiatric patients: a preliminary study. *Psychiatry Res* 1995; 61: 243–53.
- Weber S, Habel U, Amunts K, Schneider F. Structural brain abnormalities in psychopaths—a review. *Behav Sci Law* 2008; 26: 7–28.
- Woermann FG, van Elst LT, Koepp MJ, Free SL, Thompson PJ, Trimble MR, et al. Reduction of frontal neocortical grey matter associated with affective aggression in patients with temporal lobe epilepsy: an objective voxel by voxel analysis of automatically segmented MRI. *J Neurol Neurosurg Psychiatry* 2000; 68: 162–9.
- Wong M, Fenwick P, Fenton G, Lumsden J, Maisey M, Stevens J. Repetitive and non-repetitive violent offending behaviour in male patients in a maximum security mental hospital—clinical and neuroimaging findings. *Med Sci Law* 1997; 37: 150–60.
- Yang Y, Raine A, Lencz T, Bihle S, LaCasse L, Colletti P. Volume reduction in prefrontal gray matter in unsuccessful criminal psychopaths. *Biol Psychiatry* 2005; 57: 1103–8.
- Yang Y, Raine A, Narr K, Lencz T, Toga A. Amygdala Volume Reduction in Psychopaths. *Society for Research in Psychopathology Annual Meeting*. San Diego, CA: Society for Research in Psychopathology; 2006.
- Young L, Bechara A, Tranel D, Damasio H, Hauser M, Damasio A. Damage to ventromedial prefrontal cortex impairs judgment of harmful intent. *Neuron* 2010b; 65: 845–51.
- Young L, Camprodon JA, Hauser M, Pascual-Leone A, Saxe R. Disruption of the right temporoparietal junction with transcranial magnetic stimulation reduces the role of beliefs in moral judgments. *Proc Natl Acad Sci USA* 2010a; 107: 6753–8.
- Young L, Cushman F, Hauser M, Saxe R. The neural basis of the interaction between theory of mind and moral judgment. *Proc Natl Acad Sci USA* 2007; 104: 8235–40.
- Young L, Dungan J. Where in the brain is morality? Everywhere and maybe nowhere. *Soc Neurosci* 2011; May 14: 1–10.
- Young L, Koenigs M. Investigating emotion in moral cognition: a review of evidence from functional neuroimaging and neuropsychology. *Br Med Bull* 2007; 84: 69–79.
- Young L, Saxe R. An fMRI investigation of spontaneous mental state inference for moral judgment. *J Cogn Neurosci* 2009; 21: 1396–405.